# Revolution CT

Uncompromised.

Imagination at work.

# Divergent technology solutions




High definition
Iterative reconstruction

Wider detector
Shuttle mode

Dual source CT
Intelligent motion correction

Fast kV switching
Dual-layer detector

# One CT that can address all your patients

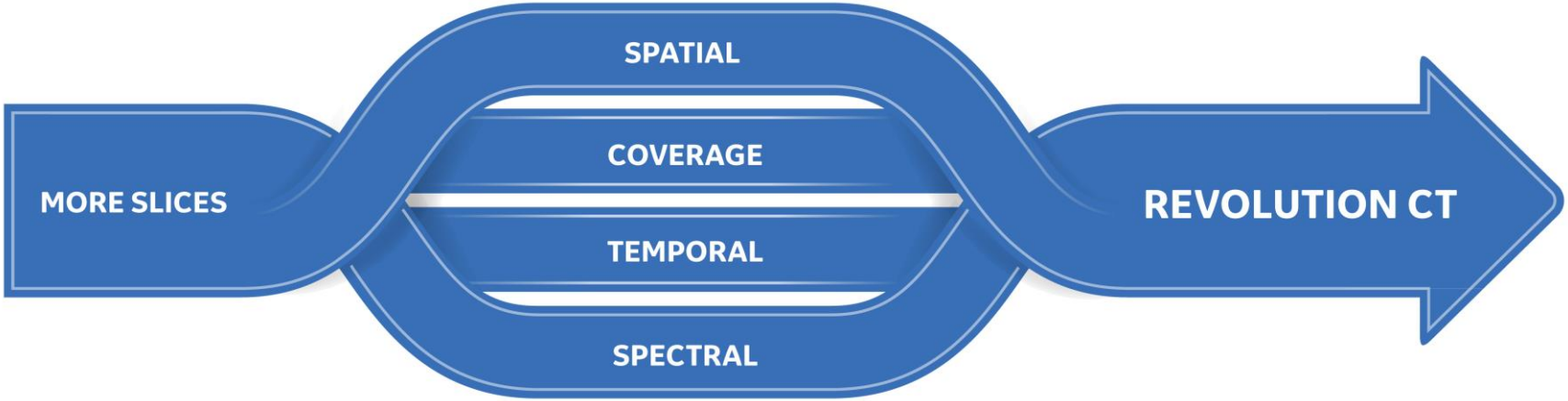


WARNING
PINCH POINT

# Gemstone detector allows you to increase spatial resolution

## 0.23 mm

### High-definition imaging

Gemstone scintillator is 100x primary speed and 4x less afterglow compared to GOS

Gemstone clarity detector overcomes challenges with typical wide coverage systems such as cone beam artifacts, scatter, beam hardening and HU uniformity

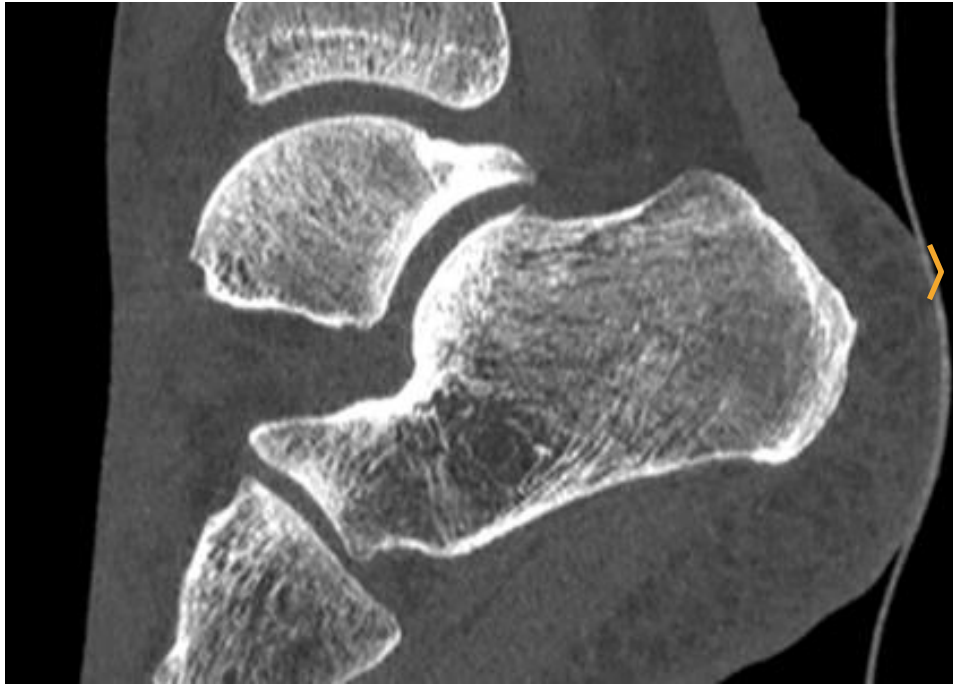

IMAGES COURTESY OF DR. J-L SABLAYROLLES, CENTRE CARDIOLOGIQUE DU NORD, SAINT-DENIS, FRANCE

# High-definition coronary CT angiography at 1.3 mSv with severe stenosis in RCA

| | |
|---|---|
| Scan type | Axial |
| Rotation time, s | 0.28 |
| Scan length, mm | 160 |
| kV | 120 |
| mA | 344 |
| Kernel | Standard |
| ASiR-V % | 50 |
| DLP, mGy-cm | 97 |
| Eff. dose, mSv | 1.3 |
| k-factor | 0.014 |

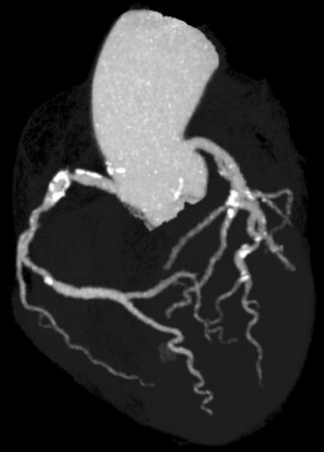

LAD

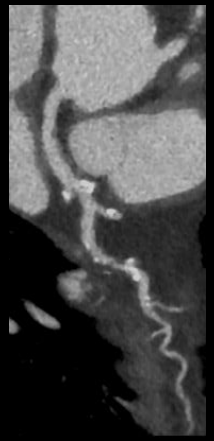

RCA



IMAGES COURTESY OF DR. J-L SABLAYROLLES, CENTRE CARDIOLOGIQUE DU NORD, SAINT-DENIS, FRANCE

# Highly-calcified coronary CT angiography in a patient with atrial fibrillation

## Acquisition

Axial 160 mm
Autogating
0.28 sec/rot
60 cc contrast
28 BMI
118-122 BPM
176 mGy-cm DLP
2.4 mSv[1]

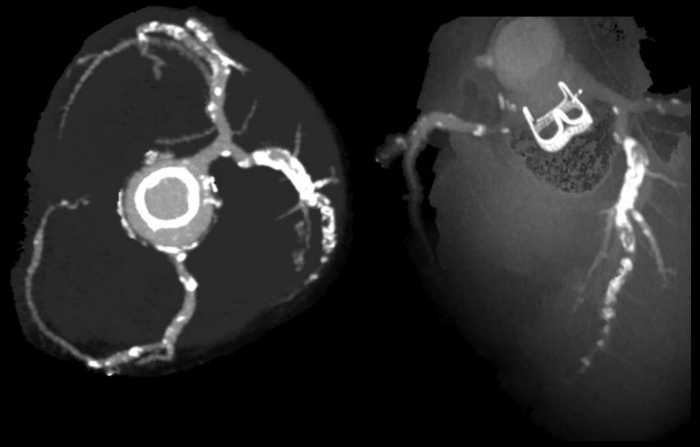

LAD

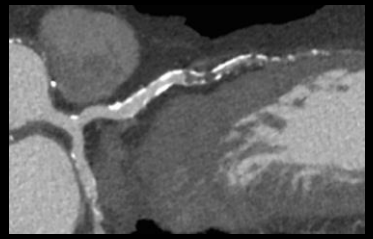

RCA

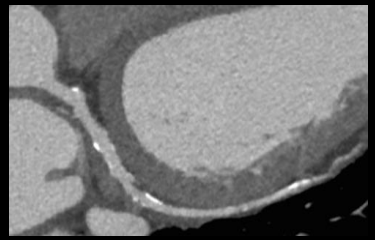

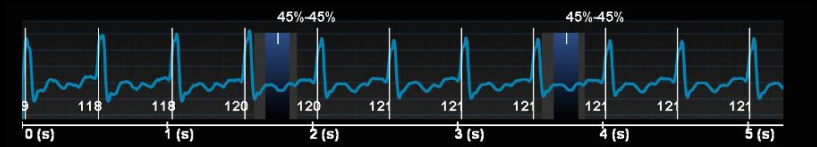


1. Obtained using a chest conversion factor of 0.014*DLP

IMAGES COURTESY OF CENTRO CARDIOLOGICO FONDAZIONE MONZINO, MILANO, ITALIA

# Cardiac CT angiography in a patient with multiple stents

## Acquisition

Axial 160 mm
One beat
0.28 sec/rot
100 kV
545 mA
27 BMI
48 BPM
50 cc contrast
HD standard kernel
ASiR-V 50%
87 mGy-cm DLP
1.2 mSv[1]

LAD

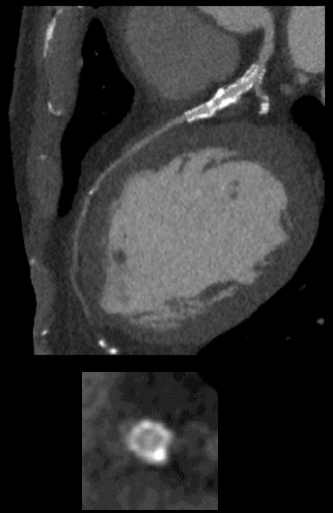

First diagonal

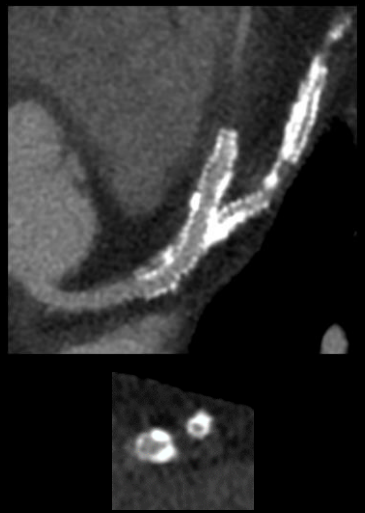

LCx

RCA

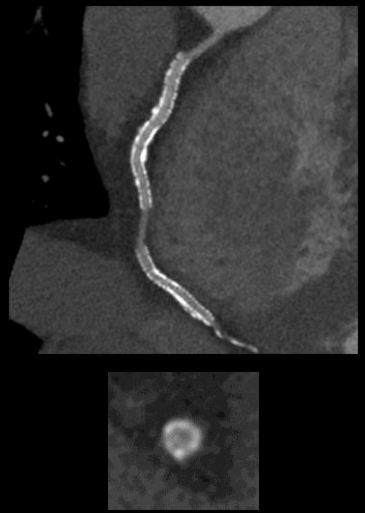

1. Obtained using a chest conversion factor of 0.014*DLP

# Flexible coverage to image entire organs in one rotation

## 160 mm

### Whole organ coverage

One-beat, motion free coronary imaging at any heart rate

Split second volume acquisitions to minimize motion artifacts and ensure contrast uniformity

HyperDrive – Up to 437 mm/s scan speed with 80 mm collimation and 1.531:1 helical pitch, across a 50 cm FOV

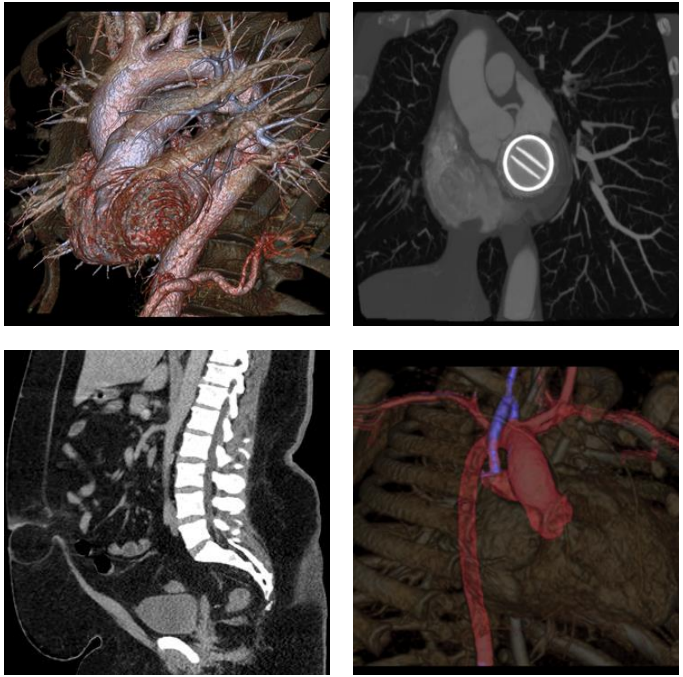

IMAGES COURTESY OF HUNTSVILLE HOSPITAL, HUNTSVILLE, AL, USA

# Trauma: Left femur fracture

| | |
|---|---|
| Scan type | Helical |
| Rotation time, s | 0.5 |
| Pitch | 0.992 |
| Slice, mm | 0.625 |
| Scan length, mm | 1784 |
| Scan time, s | 11 |
| kV | 120 |
| mA | 200-400 |
| Noise index | 13 |
| Kernel | Standard + |
| ASiR-V % | 50 |

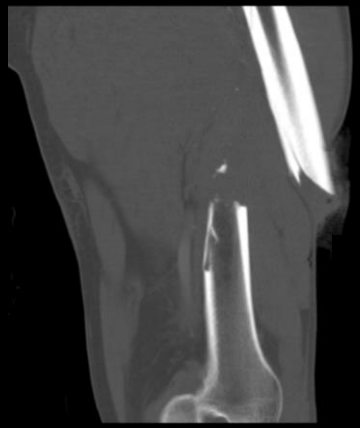

Revolution CT © 2017 General Electric Company

# GSI Xtream on Revolution CT
## Volume. Spectral. Simplified.

**Gain Insights**

Quantitative Characterization

**Fast**

2x faster image recon[1]
Ultrafast kV switching
Volume coverage

**Patient Access**

50 cm FOV

1. As compared to Revolution HD

# GSI Xtream on Revolution CT

## Volume. Spectral. Simplified.

### Simplified workflow you won't even notice

- 2x faster GSI recon throughput as compared to GSI on Revolution HD
- Native GSI recon: keV, VUE, iodine, water, fat, calcium, uric acid, and HAP
- Clinical ID and GSI assist to automate and personalize scan and recon

### Go beyond dual energy with Spectral CT

- Monochromatic images achieve 60% higher CNR than single energy CT at 120 kV[1]
- Characterize materials with quantification sensitivity as low as 0.5mg/cc with material density images[2]
- Metal artifact reduction with GSI MAR

### Volume spectral CT faster than the blink of an eye

- Ultrafast kV switching
- 50 cm GSI FOV
- 80 mm GSI collimation
- 245 mm/s GSI scan speed with 1.5:1 pitch
- Dose neutral with ASiR-V

1. Higher CNR measurement in GSI images over single kV images is demonstrated in body phantom testing at 11 and 19 mGy for 2, 5, 10, and 15 mg/mL Iodine concentrations.
*2. Detection of 0.5 mg/mL at 8 mGy is demonstrated in head phantom testing*

# Routine applications across anatomy

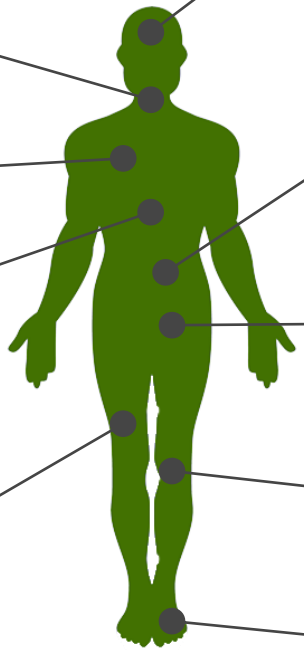

Neuro – GSI MAR to reduce metal artifacts, Monochramatic Images for posterior fossa artifacts, blood / contrast quantification

Neck – CT angiography and oncology

Chest – iodine image for PE detection combined with lung perfusion

Abdomen – Virtual unenhanced (VUE) and low keV imaging for lesion characterization

Spine – GSI MAR to reduce metal artifacts

Kidney – atomic number to help understand stone composition characterization

Angiography – low keV images to optimize contrast visualization

Orthopedics – GSI MAR to reduce metal artifacts

Gout Assessment for uric acid identification

# GSI Diagnostic Tools

- Monochromatic Images
- Material Density Images
- Virtual Unenhanced Images
- GSI Metal Artifacts Reduction
- Effective Z

# Monochromatic images (MC, or keV)

GSI can generate virtual monochromatic images as if they were imaged with a theoretical monochromatic beam; 101 user selectable energy levels which is measured in kilo electron volts (keV): 40 keV to 140 keV

- To improve CNR and enhance lesion visualization and detection at lower keV (as shown in A)
- To reduce beam hardening at higher keV (as shown in B)

Benefits

Benefits

A

50keV

70 keV

B

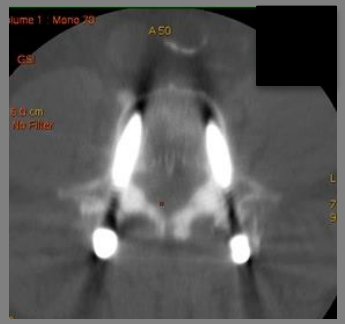

70 keV with GSI std kernel

120 keV with GSI bone kernel

# Material Density Images (MD)

GSI performs material decomposition in projection domain to natively reconstruct the material density (MD) images: iodine, calcium, water, Uric Acid, Fat, Hydroxyapetitie (HAP).

- MD images can be used to segment and measure the object's chemical composition.

Benefits

Iodine image
to show cancer metastasis lesions in spine

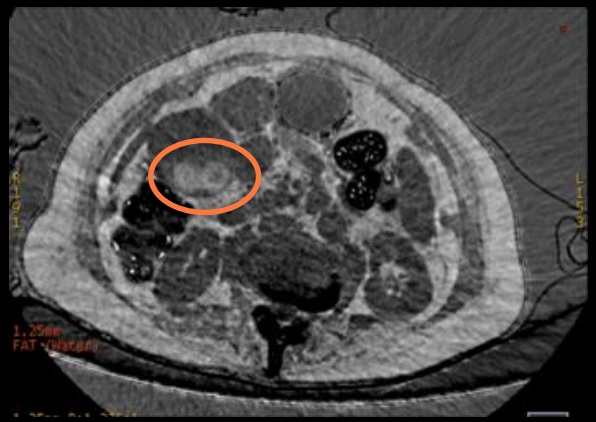

Fat image
to show cholesterol stone in gall bladder

Uric Acid image
to show gout lesion in left foot

# Virtual Unenhanced Images (VUE)

- GSI can generate virtual un-enhanced images (VUE) by subtracting iodine from images. The VUE algorithm is based on multi-material decomposition (MMD), which replaces the volume fraction of contrast by the same volume fraction of blood, producing iodine-suppressed images. The VUE images can provide attenuation information in Hounsfield units.

Benefits

VUE images provide reliable information for characterizing diverse lesions, including those with complex features.

70 keV (contrast enhanced scan)
An enhancing region (arrow) is visible in the right ureter, difficult to distinguish between a contrast medium and a calcified stone.

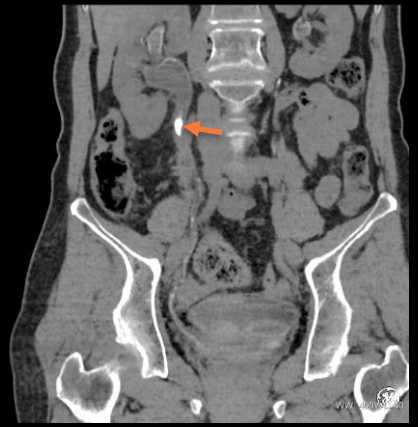

VUE (contrast enhanced scan)
shows suppression of the contrast medium and a persistent hyperattenuating lesion (arrow) which indicates calcified stone.

# GSI MAR

Benefits GSI Metal Artifact Reduction (GSI MAR) is designed to reveal anatomic details obscured by metal artifacts.

GSI without MAR

GSI MAR

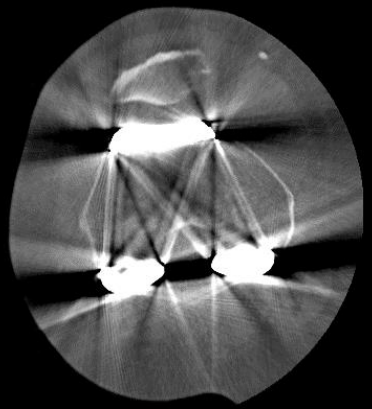

GSI without MAR

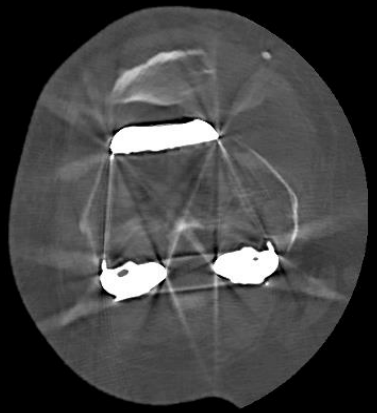

GSI MAR

# Effective Z

Benefits

Using AW GSI Viewer, GSI can generate effective atomic number (Effective Z), which is a descriptor of density and atomic number of a material, which can be used to differentiate materials.

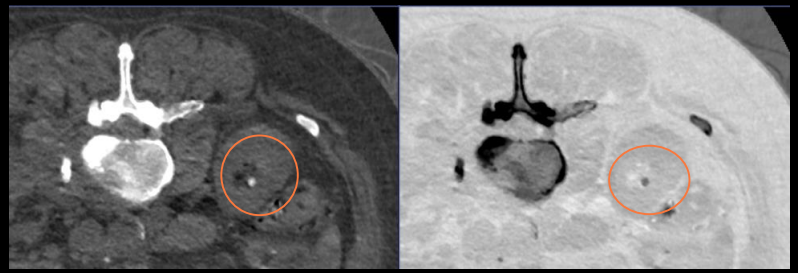

Struvite (Water) image: stone area is enhanced indicating it has struvite composition

Water (Struvite) Image

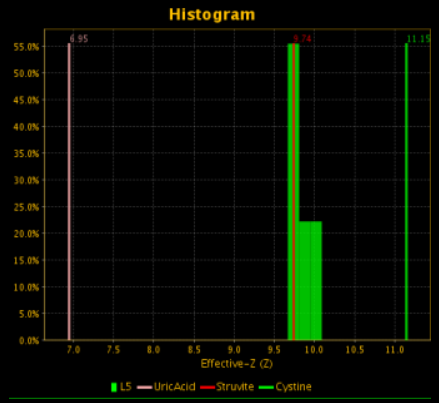


Effective Z histogram also indicating stone's composition is struvite.

Management of different stones*:

- Calcium stones: diet therapies, pharmacologic therapies
- Uric Acid stones: diet therapies, pharmacologic therapies
- Cystine stones: diet therapies, pharmacologic therapies
- Struvite stones: invasive or surgical therapies

* From 2016 MEDICAL MANAGEMENT OF KIDNEY STONES: AUA GUIDELINE

# Prioritize your patient experience

Up to **82 %**

## Reduction in dose as compared to FBP

ASiR-V is a next-generation iterative reconstruction technology designed to be used for all applications and enable routine use of dynamic acquisitions for perfusion and 4D studies

Improve LCD up to 135% at the same dose

Reduce image noise up to 91% at the same dose

Reduce streak artifacts compared to FBP

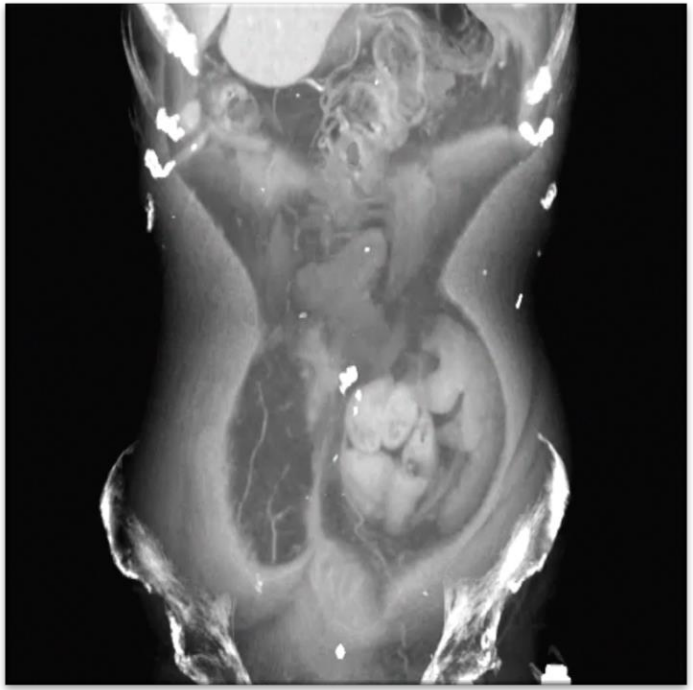

# ASiR-V and Smart Dose packages

## ASiR-V

- Reduce dose up to 82% as compared to FBP
- Real-time reconstruction

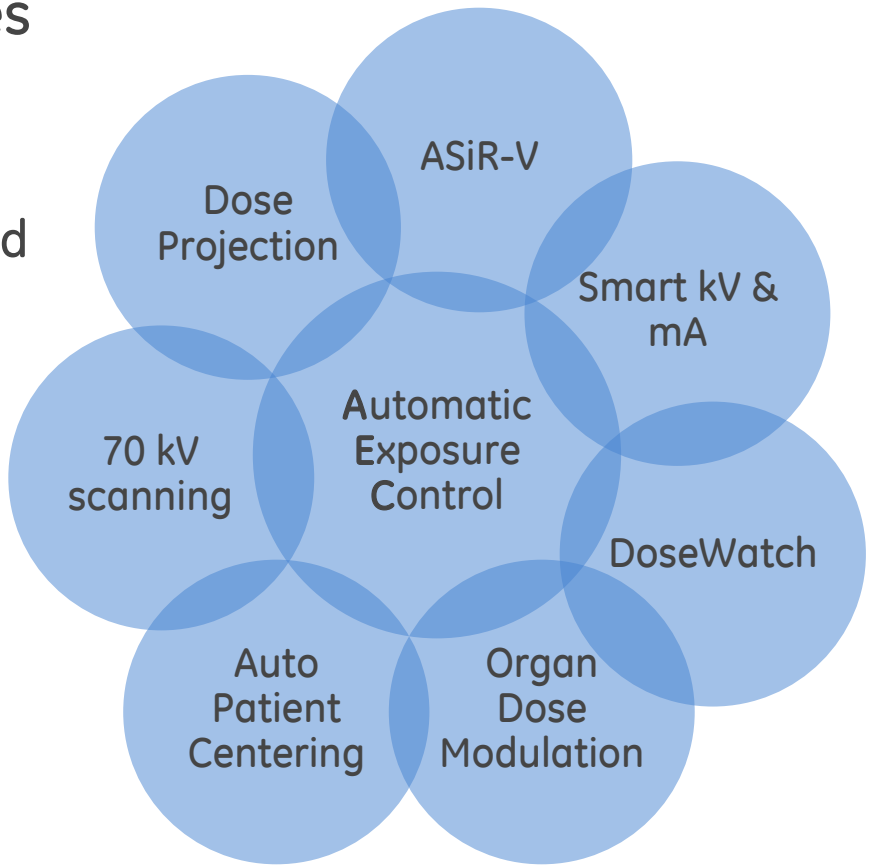

# Coronary CT angiography at 97 BPM with varying HR of 52–123 BPM and no beta blockers

| | |
|---|---|
| Scan type | Axial Gated |
| Rotation time, s | 0.28 |
| Slice, mm | 0.625 |
| kV | 120 |
| mA | 475 |
| ASiR-V % | 50 |
| CTDIvol, mGy | 15.6 |
| DLP, mGy-cm | 249.8 |
| Eff. dose, mSv | 3.5 |
| k-factor | 0.014 |

Coronary CTA from a TAVR planning exam.

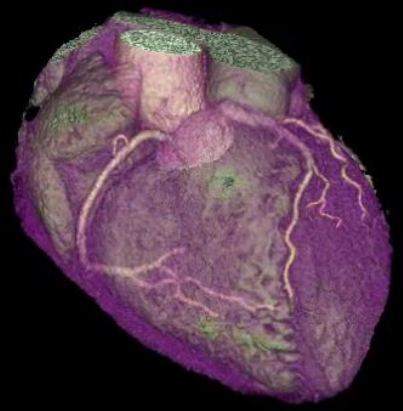

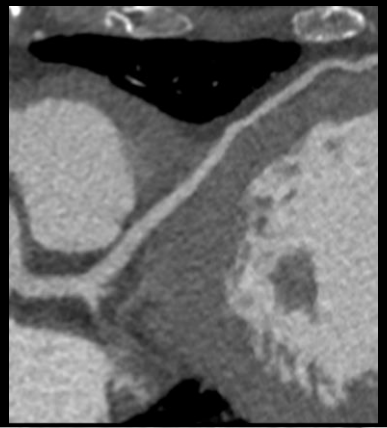

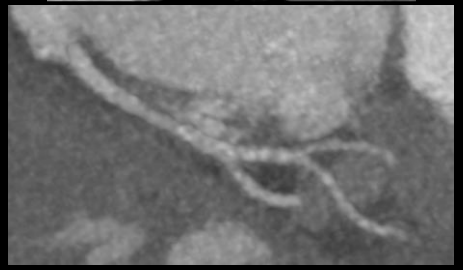

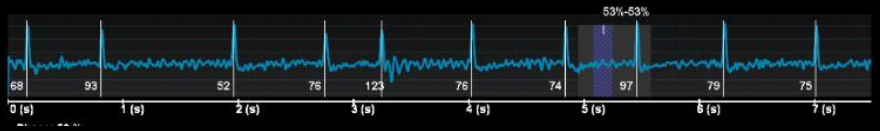


Revolution CT © 2017 General Electric Company

# Higher heart rates and atrial fibrillation patients diagnostic with Revolution CT

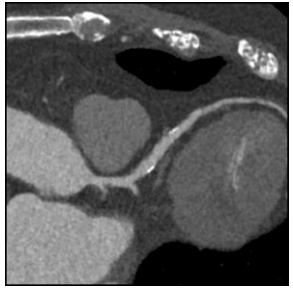

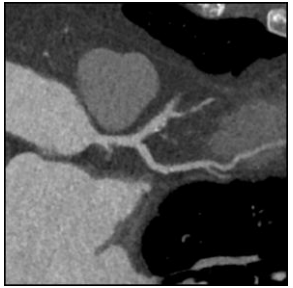

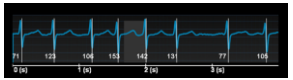


| | |
|---|---|
| Scan type | Axial |
| Rotation time, s | 0.28 |
| kV | 100 |
| Contrast, ml | 60 |
| ASiR-V % | 70 |
| DLP, mGy-cm | 125 |
| Eff. dose, mSv[1] | 1.7 |
| BMI | 35 |
| BPM | 71-153 |
| One beat | |

IMAGES COURTESY OF PROF. SCHMITT, HERZ-UND GEFÄSSKLINIK, BAD NEUSTADT AN DER SAALE

Atrial Fibrillation vs. sinus rhythm on Revolution CT:

*"The analysis of our initial experience shows that the quality of all images obtained through 256-MDCT in AF patients **meets the demands of diagnosis.**"*

Image quality of 256-multidetector computed tomography in patients with atrial fibrillation: an initial experience, Chen et al, European Heart Journal, Vol 17, http://eurheartjsupp.oxfordjournals.org/content/17/suppl_F/F32

High heart rates with no rate control on Revolution CT vs. 64 slice MDCT:

*"Our prospective pilot study identified **significant improvements** in **image quality and SNR** through the use of a new volumetric large detector scanner enabled with wide cone beam reconstruction software. Importantly, this improvement was realized **despite imaging at higher heart rates**. There were also significant improvements in both **blood pool and myocardial signal homogeneity**."*

Comparison of image quality, and diagnostic interpretability of a new volumetric high temporal resolution scanner versus 64-slice MDCT, Raju et al, Elsevier, Clinical Imaging, 2016 , http://www.clinicalimaging.org/article/S0899-7071(15)00276-4/abstract

# Dynamic cardiac movie

85 BPM, cardiac phase 30%-280%

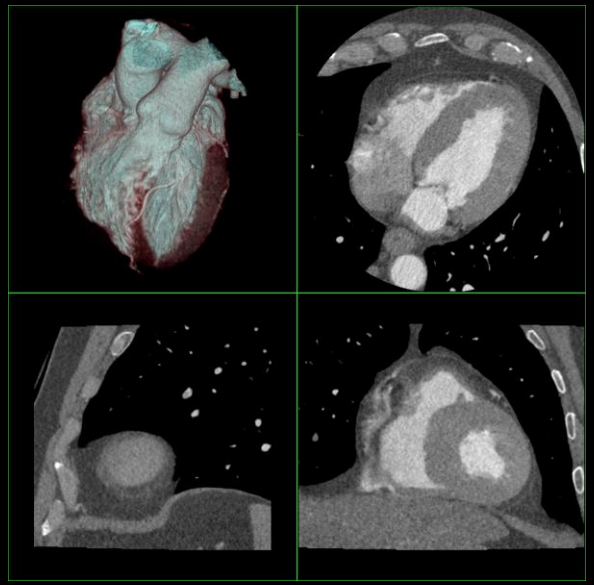

30%

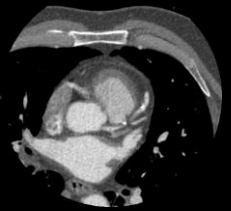

130%

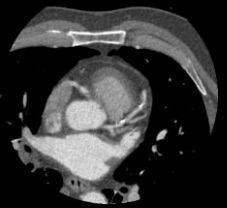

230%

# Myocardium wall analysis

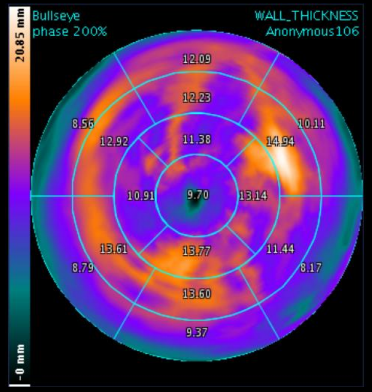


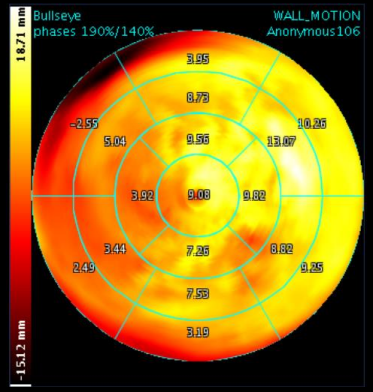


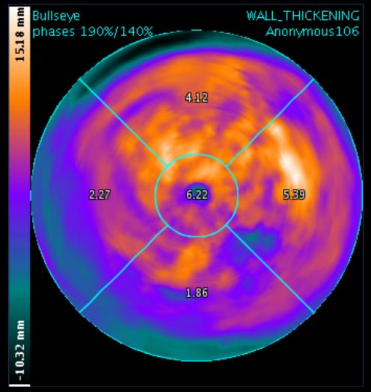

IMAGES COURTESY OF DR. J-L SABLAYROLLES, CENTRE CARDIOLOGIQUE DU NORD, SAINT-DENIS, FRANCE

# Dynamic cardiac perfusion with coronary artery visualization

## Acquisition

Axial 160 mm
0.28 sec/rot

Wash-in
10 passes
100 kV
500 mA

Wash-out
5 passes
100 kV
250 mA

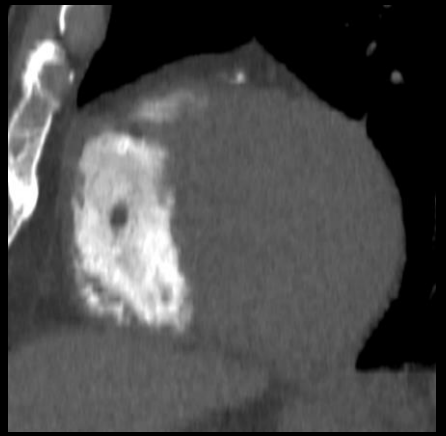

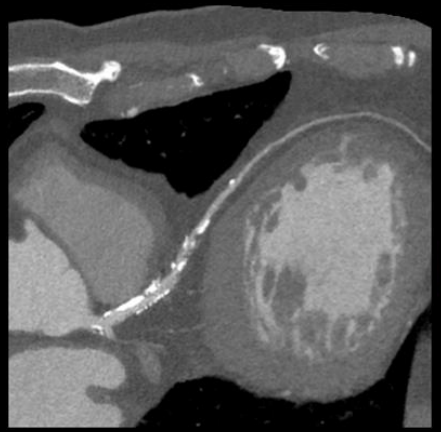

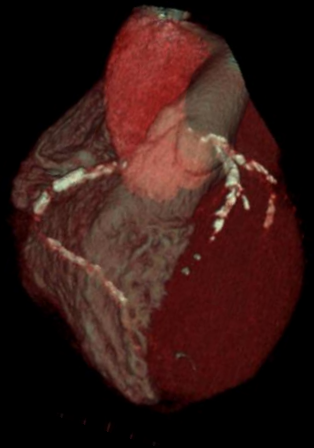

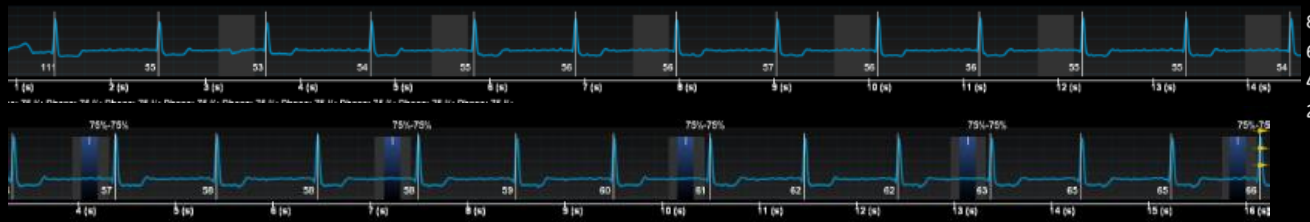

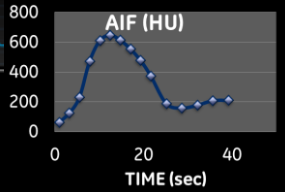

# Rest/stress 3 mSv[1]
# 53 BPM resting, 84 BPM stress, cardiac phase 70%

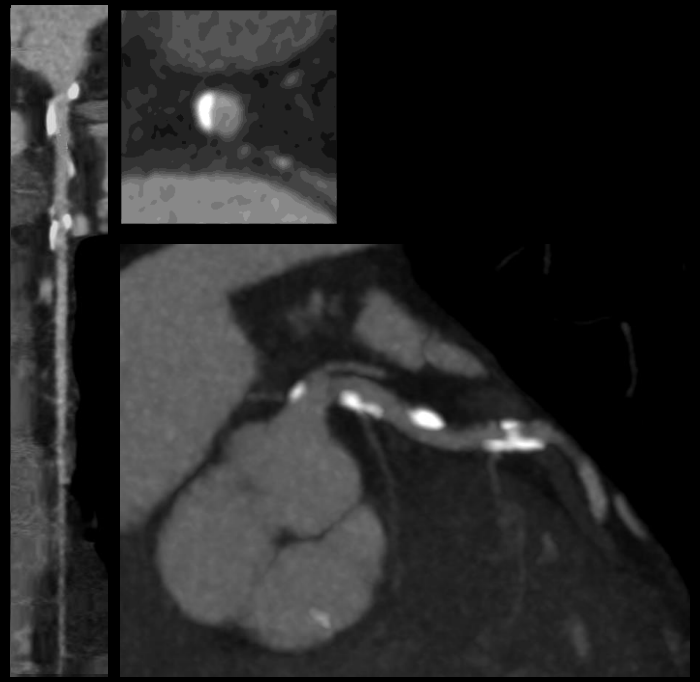

Rest

1. Obtained using a chest factor of 0.014*DLP

# Rest/stress 3 mSv[1]
# 53 BPM resting, 84 BPM stress, cardiac phase 70%

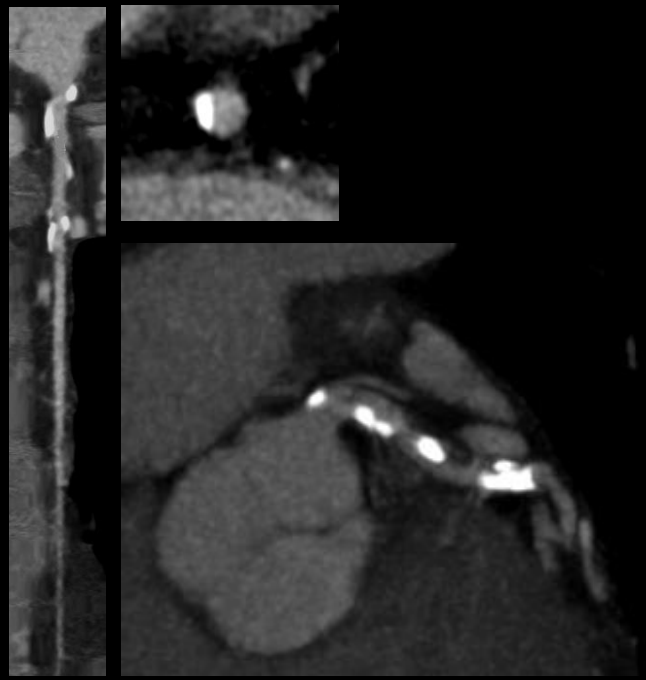

Stress

1. Obtained using a chest factor of 0.014*DLP

# TAVI/TAVR planning
# 87 BPM, cardiac phase 50%

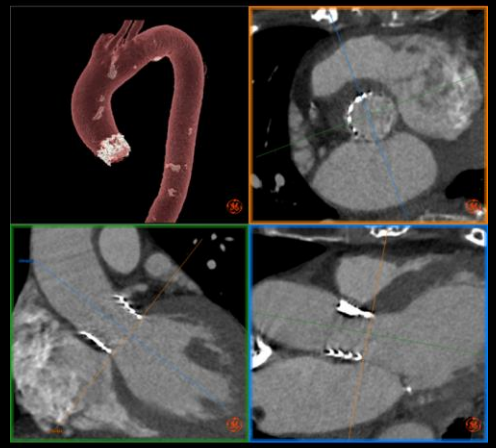

Aortic arch

Uniform contrast throughout entire image

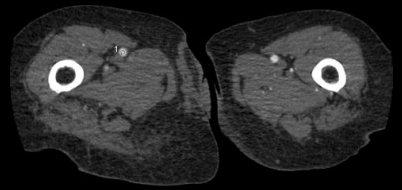

Femoral

# Perfusion
## Sample every 2 s for 20 s, sample every 5 s for 30 s, 3.6 mSv[1]

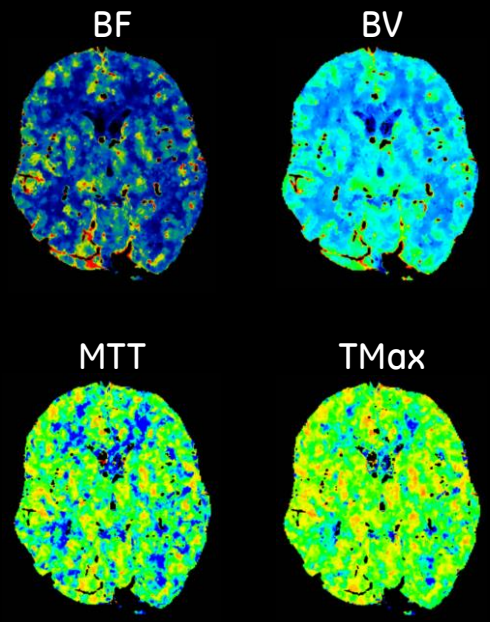


1. Obtained using a head factor of 0.0023*DLP

# Whole brain perfusion & CTA

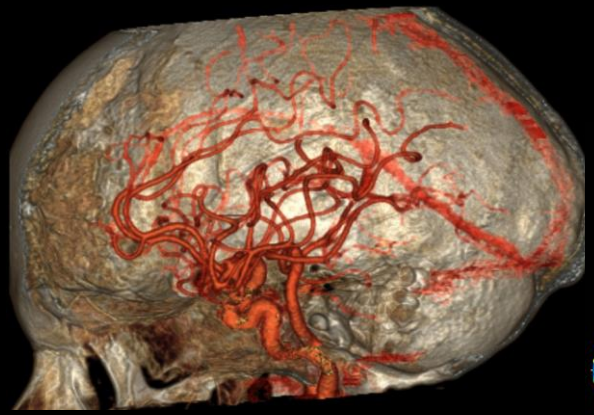

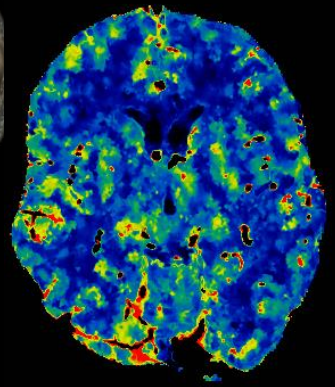

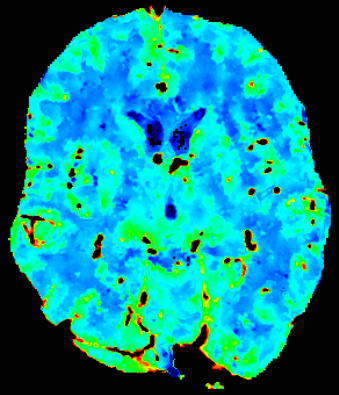

# Circle of Willis – 0.9 mSv[1]

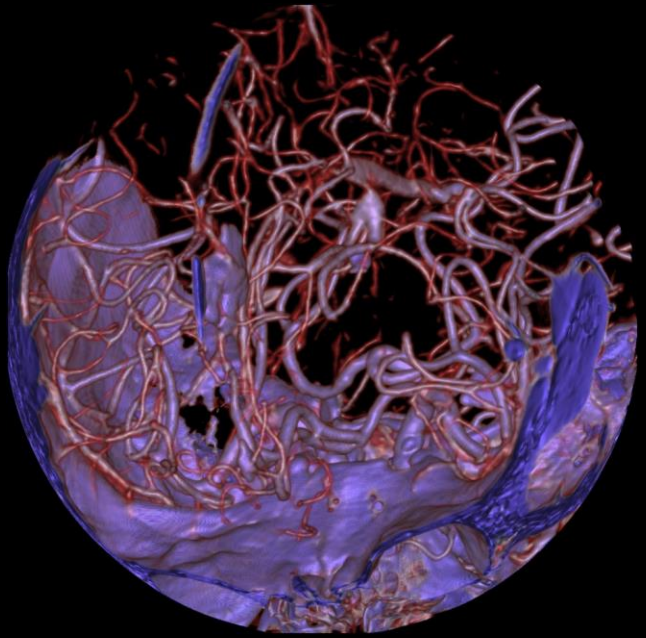

1. Obtained using a head factor of 0.0023*DLP

# Carotids
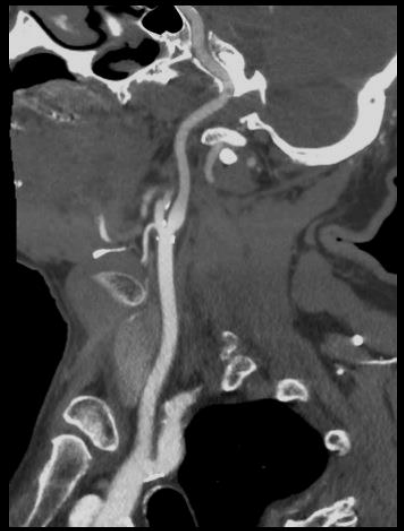
# Carotids